

# Toxicity of dimethoate on Histopathological alteration in Liver of freshwater fish, *Arius Dussumieri*

Dnyaneshwar Sawairam Rathod

Assistant professor

Department of Zoology and Fishery Science

Rajarshi Shahu Mahavidyalaya, Latur (M.S.) India.

E-Mail: dr\_dsrathod@rediffmail.com

## Abstract

In this study, trial has been made to verify the toxicity of dimethoate on histopathological alteration in the liver of fish, *Arius Dussumieri*. First lethal and Sublethal concentration of dimethoate against the test fish (  $LC_{50}$  is 5.99 and  $1/10$  of  $LC_{50}$  0.599 ) respectively was obtained. The laboratory acclimatized fishes were exposed to lethal and sublethal concentration of toxicant dimethoate and observed after 24 hours to 96 hours. Liver exposed to sublethal concentration of dimethoate showed significant changes compared to control structure of liver. There was hypertrophy of hepatic cells and the cells were disorganized, finally forming homogenous mass, loss of polygonal shape of hepatocytes, loss of liver cord orientation, breakdown of sinusoids. Fragmentation of nuclei, cell without nuclei and granular cytoplasm of the hepatocytes were observed in liver of exposed fish.

**Key Words:**  $LC_{50}$ , Histopathology, Dimethoate, *Arius Dussumieri*.

## Introduction:

Developmental activities of industrialization and urbanization are depleting the natural resources of our environment, resulting in environmental degradation.

Pesticides play important role in increasing agricultural productivity by controlling pests. But on other hand, they cause much damage to the non-target organisms both in terrestrial and aquatic environment. Pesticides are the chemicals, which have posed potential health hazard not only to livestock and wild life but also to fishes, birds, mammals and even human beings.

India ranks third in the world in terms of consumption of pesticide and its production has increased several hundred folds during last four decades (Chhokar, 2001). (1)At present there are sixteen major and many minor pesticide-manufacturing industries engaged in production of various pesticides. The manufacturing process of these compounds is such that it generates lot of toxic waste water. This wastewater finds its way into the aquatic environment, directly or indirectly and cause contamination of water bodies, which may lead to mortality of aquatic organisms. (Leonard, *et al.*, 1999). (2)

Histology is an important tool for determining the action of any toxicant at tissue level, providing data concerning tissue damage (Sprague, 1971). (3)

Histopathology deals with the study of pathological changes induced in the microscopical structure of body tissue. Any peculiar alteration of cells may indicate the presence of disease or the effect of toxic substance.

A review of literature shows that numerous histopathological changes have been reported in fishes exposed to the various pollutants. Physiological studies alone do not satisfy the complete understanding of pathological conditions of tissue under toxic stress. Hence the histopathological studies were undertaken with a view to study the changes in the vital tissues like gill, liver, kidney and intestine of *Arias dussumieri*.

### Materials and Methods:

For the study of Histopathological effects the live test fish, *Arias dussumieri* were collected from Manjara River, Latur and brought to laboratory. The test fish, *Arias dussumieri* were exposed to 96 hrs LC<sub>50</sub> and 1/10<sup>th</sup> of 96 hrs LC<sub>50</sub> concentration of dimethoate. (5.99 and 0.599 ppm) respectively. Fishes showing normal activity were selected for each test. Simultaneously a control was also maintained. At the end of acute exposure (96 hr) the survived fish were decapitated and immediately the tissue of liver was removed and fixed in aqueous bouin's fluid for 24 hours.

The tissue was dehydrated in different grade of alcohol and blocks were prepared in paraffin wax (60-62°C). The sections of 5-6 μ thickness were cut and stained with hematoxyline and Eosin and then mounted in DPX.

### Results:

In the present investigation, the histopathological alterations induced by treatment of dimethoate in liver tissue were observed.

### Histology of Liver:

It is largest gland in the body situated near the stomach. It is formed of two lobes. On ventral side of stomach, there lies a green sack like structure called gall bladder which stores the secretion of liver called bile.

Histologically the liver is covered by a white fibrous connective tissue sheath called Glisson's capsule. It consists of hepatic lobules. Each hepatic lobule is made up of rows of hepatic cells. Hepatic cells contain granules of glycogen, fat droplets, iron ions and pigment granules. The space between the hepatic cords is known as sinusoids which contain phagocytic Kuffer's cells.

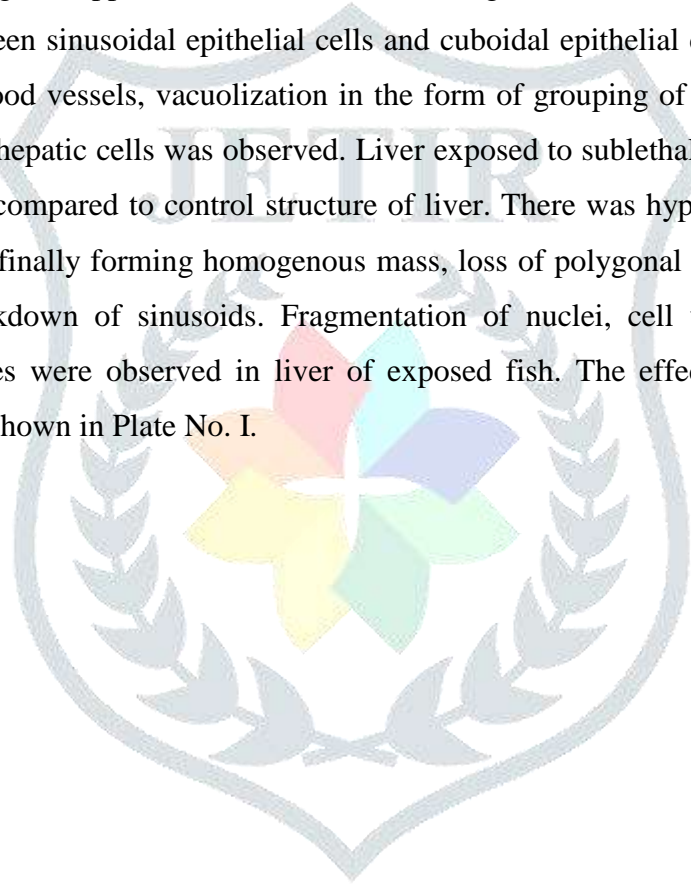
Each hepatocytes shows clear cytoplasm and distinct central rounded nucleus with nucleoli. These hepatocytes are arranged in cords and separated from adjacent one by blood space. The blood space is lined by connective tissue. The liver has no direct contact with pollutants. Pollutants reach to liver through blood. Liver is susceptible to number of toxic and metabolic disturbances.

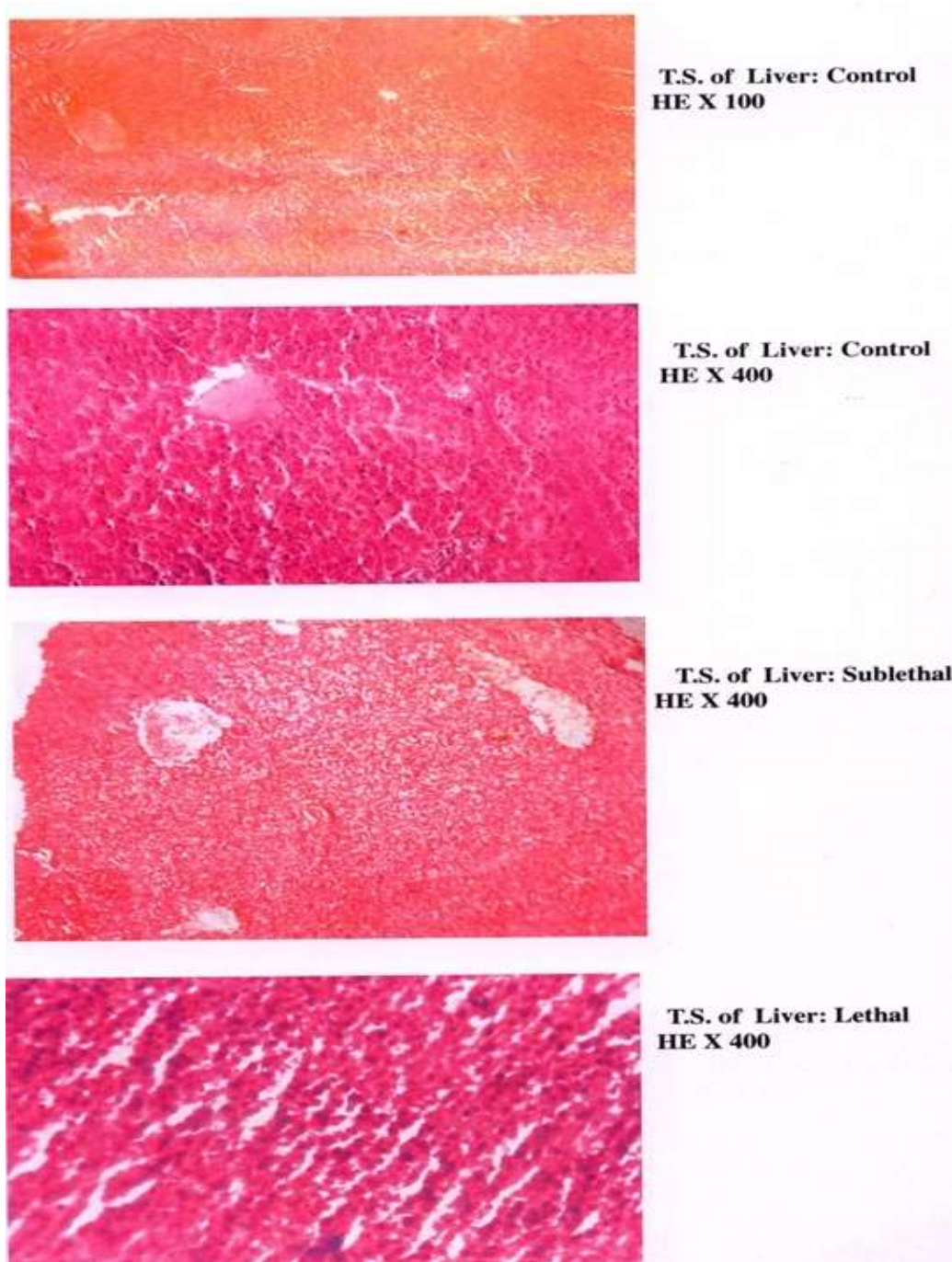
### **Histopathology of Liver:**

Liver is an important organ helping not only in digestion but also in detoxification of toxic substances or toxicants or pollutants entering in an organism through environmental contamination. There is no contact of liver with pollutants but pollutant reach liver through blood.

In present investigation, toxicant like dimethoate entered into the liver through blood and caused adverse effect on its structure and function. Liver being an organ to metabolize and eliminate toxicant shows visible abnormalities when compared to control fish.

The liver of fish exposed to lethal and sublethal concentration of dimethoate showed following structural damages. Liver exposed to lethal concentration of dimethoate showed damage of peripheral hepatocytes resulting in loss of their polygonal appearance. Liver cord disarrangement, extensive degeneration of cytoplasm and appearance of gap between sinusoidal epithelial cells and cuboidal epithelial cells i.e. hepatic parenchyma cells are less. Rupture of blood vessels, vacuolization in the form of grouping of large number of blood cells, vacuolation in cytoplasm of hepatic cells was observed. Liver exposed to sublethal concentration of dimethoate showed significant changes compared to control structure of liver. There was hypertrophy of hepatic cells and the cells were disorganized, finally forming homogenous mass, loss of polygonal shape of hepatocytes, loss of liver cord orientation, breakdown of sinusoids. Fragmentation of nuclei, cell without nuclei and granular cytoplasm of the hepatocytes were observed in liver of exposed fish. The effect of dimethoate on liver to different exposure period is shown in Plate No. I.





**Plate-I :** Histology of Liver at variable concentration of dimethoate

### **Discussion:**

Datta *et al.* (1992) (4) studied effect of Malathion on histopathological changes in liver of freshwater catfish, *Heteropneustes fossilis* and reported that the degenerative changes in liver cells.

Bhatnagar and Bana (1993) (5) studied effect of thiodon and rogor on histopathological changes in liver of *Channa gachua* and reported that the destruction in the liver caused by pesticides resulted in the destruction of lysosomal bodies containing this enzyme.

later on Padhya and his co-workers had been noted an effect upon cirrhosis and dysplasia caused by sunset yellow and brilliant blue in the liver of *Hetropneustes fossilis* and reported that fissures radiating throughout the tissue were also prominent during 3rd and 4th week were observed in the liver of *Hetropneustes fossilis* exposed to sunset yellow and brilliant blue for two months.

Bhatnagar *et al.* (1994) (6) observed necrosis, space formation and blood cell accumulation. Liver is the chief metabolic and detoxicating organ.

Kumari and Rajkumar (1997) (7) studied effects of polluted water on histochemical localization of carbohydrate on fish *Channa punctatus* and observed the carbohydrate content of the hepatic cells from the polluted water fish also decreased drastically.

Yadav (2001) (8) reported that the liver in the albino rat also showed cirrhosis of liver that impaired its function such histopathological changes were observed following exposure to textile dye waste waters.

Lerley Sounderaj *et al.* (2001) (9) studied on haematological and histopathological responses of *Rana tigrina* to a sublethal concentration of heavy metal chromium and observed that the liver of treated animal reveals hyperactivity with less intercellular space, granular cytoplasm and enlarged nuclei compared to control.

Sakthival and Gaikwad (2002) (10) studied toxicity of dimecron on tissue histopathology of *Gambusia affinis* and reported that the necrosis in liver effect on hepatocytes, hyperplasia and rupture of the cell membranes resulting in multinucleated regions and accumulation of R.B.C.

Anita Susan and Tilak (2003) (11) studied on histopathological changes in the vital tissue of the fish *Cirrhinus mrigala* and observed that the fenvalerate had induced discrete pathological changes in the liver tissue of experimental fish. These changes include degeneration of cytoplasm in hepatocytes, atrophy and rupture in blood vessels, causing the appearance of blood streaks.

Rana and Yergi (2004) (12) worked on histopathological alteration induced by pesticide on the mudskipper and reported the liver of fish treated with fenvalerate for two weeks were clumping of hemolytic in blood sinusoids and accumulation of hemolytic in cellular spaces and vacuolation of blood vessels were noticed after exposure period of four weeks to cypermethrin.

Nagrajan and Aruna Devi (2006) (13) studied histological changes in Indian fresh water fish carp *Labeo rohita* due to effects on distillery effluent and observed that the space of disse, the gap between sinusoidal epithelial cells and cuboidal epithelial cells is less. All the cells of the hepatic parenchyma are of similar size. The shape of the parenchyma cells is altered and the space of tissue is comparatively more. later on sultana and Rajan studied on histopathological changes in the liver by copper sulphate, lead nitrate, and zinc sulphate of *Tilapia mossambica* and reported that the after exposure to heavy metals included necrosis of liver parenchyma,

hyperplasia and rupture of cell membrane resulting in multinucleated regions and accumulation of R.B.C. the lead has affected severely in the liver vacuolation is occurs.

Change in histology of liver due to exposure of dimethoate was vacuolation in cytoplasm, loss of polygonal shape of hepatocytes, loss of liver cord orientation etc. Changes observed in kidney due to exposure of dimethoate were expansion in renal tubules, vacuolization in epithelial cells of renal tubules

### References:

1. Chhokar R.S. (2001): Development and use of herbicides pesticide information 27: 24-27pp. Conillard, C.M., Berman, R.A. and Banisset, J.C. (1988): Histopathology of rainbow trout exposed to bleached kraft pulp mill effluent. *Arch. Environ. Contam. Toxicol*, 17(3): 319-323pp.
2. Leonard, A. Hyne, R.V., Lim, R.P. Chapman, J.C. (1999): Effect of endosulfan run-off from cotton field on macro invertebrate in Normal River, Ecotox, *Environ Safe* 42: 125-134pp.
3. Sprague (1971) : Measurement of pollutant toxicity of fish III Sublethal effects and 'Safe' concentrations *Water Res.*, 5 : 245-266pp.
4. Datta H.M., Adhikari S., Singh N.K., Roy, P.K. and Munshi, S.D. (1992): Histopathological changes induced by Malathion in the liver of a fresh water catfish *Hetropneustes fossilis* (Bioch) *Bull. Environ. Contam. Toxicol*, 51: 895-900pp.
5. Bhatnagar, M.C., M.Tyagi and A.K. Bana (1994): Neurotoxicity in *Clarias*, *Proc. Acad. Environ. Bio.* 3(1): 119pp.
6. Bhatnagar, M.C. and Bana, A.K. (1993): Pesticide induced histopathological alterations in liver *Channa gachua* *Proc. Acad. Environ. Biol.* 2: 115-118pp.
7. Kumari Anitha S. and Rajkumar N. Shree (1997): Effect of polluted water on histochemical localization of carbohydrates in freshwater *Channa punctatus*, from Hussainsagar Lake, Hyderabad Andhra Pradesh, *Pollu. Res.* 16: 197-200pp
8. Yadav, R.K. (2001) Effect of textile waste water from Sanganer on general metabolism and reproductive system of male albino rat (with special reference to biochemical and histochemical approach) Ph.D. Thesis, University of Rajasthan, and Jaipur, India.
9. Lerley Sounderaj, A. Nancy and I. Christy (2001): Haematological and Histopathological responses of *Rana tigrina* to a sublethal concentration of heavy metal chromium. *Aquatic, pollution and toxicology, ABD Pubs. Jaip. Rajasthan India* 51-58pp.
10. Sakthivel Veena and Gaikwad, S.A. (2002) Tissue histopathology of *Gambusia affinis* (Baird and Girard) under dimecron toxicity, *Eco. Env. And Cons.* 8(1): 27-31pp.
11. Anita Susan, T. and Tilak, K.S. (2003): Histopathological changes in the vital tissues of the fish *Cirrhinus mrigala* exposed to fenvalerate Technical grade. *Poll. Res.* 22(2): 179-184pp.

12. Rana and Yergi (2004) : Histopathological alterations induced by pesticides on gill and liver of the mudskipper *Beleopthalmus dussumieri* *J. Comp Toxicol, Physiol.* Vol. I (III & IV) 190-194pp.
13. Nagrajan and Aruna Devi (2006); Histopathological changes in Indian freshwater major carp. *Labeo rohita* due to distillery effluent. *Nature Environment and pollution technology*, 5 (1): 1-6pp.

